

## Morphometry of the Acetabulum of Dry Hip Bones in Adult Human

\*Md Alamin Sheikh,<sup>1</sup> Opu Rani Podder<sup>2</sup>

### ARTICLE INFO

#### Article history:

Received: 11 March 2025

Accepted: 07 June 2025

#### Online:

www.nbmc.ac.bd

#### Keywords:

Morphometry, Hip bone,  
Acetabulum

### ABSTRACT

**Introduction:** The knowledge on normal anatomical features and morphometry of the acetabulum is vital to understand the normal mechanics of hip joint. The study intended to determine the morphometric analysis of the acetabulum of dry hip bones in adult human of Bangladesh. **Methods:** This cross-sectional type of descriptive study was conducted in the Department of Anatomy, Rajshahi Medical College, Rajshahi over a period of one year from July, 2021 to June, 2022. This study was performed on 247 (right sided 127 and left sided 120) dry hip bones of adult human collected from the Department of Anatomy of different Medical Colleges in Rajshahi division of Bangladesh on the basis of selection criteria. Data were collected purposively with the help of a structured data collection form. **Results:** The mean diameter of acetabulum was  $48.53 \pm 3.66$  mm, mean depth was  $27.88 \pm 3.33$  mm and the mean volume was  $32.14 \pm 7.55$  ml. All the morphometrical parameters were found to be higher in left side than right side. Diameter, depth and volume were higher in left side than right but statistically non-significant ( $p > 0.05$ ). There was statistical significant positive correlation between diameter and depth of the acetabulum ( $p < 0.001$ ). **Conclusion:** Diameter, depth and volume of acetabulum were higher in left side than right. This might help the anatomists, forensic experts, anthropologists, orthopedic surgeons and prosthetists to deal with their professional works.

1. Assistant Professor, Department of Anatomy, North Bengal Medical College, Sirajganj, Bangladesh
2. Assistant Professor, Department of Anatomy, Khwaja Yunus Ali Medical College, Sirajganj, Bangladesh

\*Corresponding author: ✉ dr.alaminsheikh290385@gmail.com

### INTRODUCTION

**H**ip joint is a large joint that connects the appendicular skeleton to the axial skeleton. It transmits the weight of the body. It is one of the most important anatomical structures of the body that provides continuous and regular movements of the lower extremity. The structure that makes the joint so important is the acetabulum which is located on the anterolateral surface of hip bone.

Acetabulum is a cup shaped cavity which articulates the head of the femur on the outer

surface of the hip bone. It consists of three parts (ilium, ischium and pubis) bounded by a ridge known as rim of acetabulum.<sup>1</sup> Inside the acetabulum there is a horseshoe shaped articular cartilage and acetabular fossa which is filled with fibroadipose tissue and covered by synovial membrane in the middle. The acetabulum is an approximately hemispherical cavity surrounded by an irregular margin deficient inferiorly at the acetabular notch. The pubis forms the anterosuperior one fifth of the articular surface,

the ischium forms more than the poster-inferior two-fifth and the ilium the remainder.<sup>2</sup>

The diameter and depth of acetabulum are considered during surgical treatment of acetabular fractures.<sup>3</sup> When total hip arthroplasty (prosthesis) is planned measurement values of acetabulum are needed, which can affect the position and stability of the acetabular component.<sup>4</sup> Anatomical features and morphometry of the acetabulum are important for understanding of the mechanics of hip joint. This information acts as a basis for the making of hip joint prosthesis. An incongruous joint is more prone to develop degenerative changes than a joint having normal anatomy.<sup>5</sup> A bigger roof of the acetabular cup means a good grip of the head of the femur inside the acetabulum and hence a better result of arthroplasty.<sup>6</sup> Two types of hip disease, acetabular dysplasia and femoro-acetabular impingement, are associated with morphological abnormalities of the acetabulum, including acetabular diameter, depth and orientation.<sup>7</sup> The relative preponderance of the articular area in relation to non-articular area would indicate better adaptation and gripping of the head of the femur inside the acetabular socket. The grasp for the head of the femur might be weaker to produce a comparatively less stable hip joint.<sup>8</sup> Acetabular reconstruction and planning reorientation procedures using spikes and screws for fixation requires thorough knowledge of acetabular anatomy. There is a racial difference in Thais, Chinese, Nigerians and other populations.<sup>9</sup>

However, there are limited studies done in Bangladeshi population. Therefore, this study was aimed to analyse the Morphometry of the Acetabulum of Dry Hip Bones in Adult Human of Rajshahi Medical College, Rajshahi, Bangladesh.

## METHODS

This cross-sectional type of descriptive study was conducted in the Department of Anatomy, Rajshahi Medical College, Rajshahi over a period of one year from July, 2021 to June, 2022. It was performed on 247 adult human dry hip bones (right sided 127 and left sided 120 ) collected from the Department of Anatomy, Rajshahi Medical College, Rajshahi as well as other Medical Colleges fulfilling the inclusion criteria. The morphometric parameters were diameter, depth and volume of the acetabulum. Diameter of the acetabulum was measured by taking distance between the acetabular ridge nearest to the ischial tuberosity to anterior iliac margin intersecting the acetabular ridge using a digital sliding vernier caliper. The depth of the acetabulum was measured by using a thin metallic strip placed across the brim of the acetabular cavity and then the distance from the metallic strip to the deepest point in the acetabulum have measured by using the vernier caliper. Volume of the acetabulum was measured by filling the cavity with plasticine up to its brim and then the plasticine transferred to a water filled graduated measuring cylinder. The volume of water displacement was taken as the capacity of the acetabular cavity. Data were collected purposively with the help of a structured data collection form. The measurements were done by using digital sliding vernier calipers and graduated measuring cylinder. The data were analyzed via SPSS (version 24.0). P value <0.05 was consider as statistically significant.

## RESULTS

The mean diameter, depth and volume of acetabulum were  $48.53 \pm 3.66$  mm,  $27.88 \pm 3.33$  mm and  $32.14 \pm 7.55$  ml respectively (Table I).

**Table I: Morphometric parameter of the acetabulum (n-247)**

Morphometric parameters	Mean±SD	Median	Mode	Minimum	Maximum
Diameter (mm)	$48.53 \pm 3.66$	48.70	46.01	38.34	58.55
Depth (mm)	$27.88 \pm 3.33$	27.18	28.17	11.29	37.46
Volume (ml)	$32.14 \pm 7.55$	31.00	20.17	16	57

Mean diameter of acetabulum of right side was  $48.31 \pm 3.54$  mm and left side was  $48.75 \pm 3.78$  mm. Mean depth was  $27.79 \pm 3.29$  mm in right side and  $27.97 \pm 3.39$  mm in left side. Right sided mean volume was  $31.63 \pm 7.01$  ml and  $32.68 \pm 8.08$  ml in left side. Mean diameter, depth and volume of acetabulum were higher in left side than right (Table II).

**Table II: Morphometry of acetabulum on the basis of side (n-247, Right-127, Left-120)**

Morphometric parameter of acetabulum	Side	Mean ±SD	Standard Error of Mean	Variance	Maximum	Minimum
Diameter (in mm)	Right	48.31±3.54	0.31478	12.584	56.55	40.95
	Left	48.75±3.78	0.34586	14.355	58.55	38.34
Depth (in mm)	Right	27.79±3.29	0.29243	10.86	35.07	11.29
	Left	27.97±3.39	0.30950	11.495	37.46	15.86
Volume (in ml)	Right	31.63±7.01	0.622	49.187	50	20
	Left	32.68±8.08	0.738	15.31	57	16

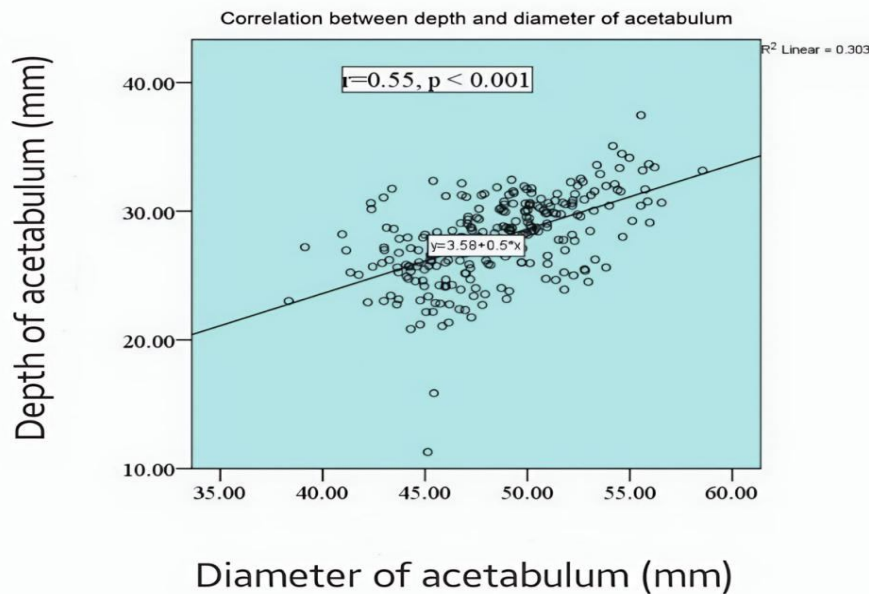
The diameter, depth and volume were higher in left side than right but all the parameters were statistically non-significant ( $p>0.05$ ) (Table III).

**Table III: Relationship of diameter, depth and volume of acetabulum between right and left sided hip bones (n-247; Right-127, Left-120).**

Morphometric parameter	Side	Mean ±SD	Mean difference	t value	p
Diameter (in mm)	Right	48.31±3.54	0.43	0.93	>0.05
	Left	48.75±3.78			
Depth (in mm)	Right	27.79±3.29	0.18	0.43	>0.05
	Left	27.97±3.39			
Volume (in ml)	Right	31.63±7.01	1.05	1.09	>0.05
	Left	32.68±8.08			

\*Independent Sample t-test was used to analyze data

Significant ( $r=0.55$ ,  $p<0.001$ ) positive correlation (Pearson’s correlation coefficient test) was found between depth and diameter of acetabulum (Figure 1).



**Figure 1: Scatter diagram showed correlation between depth and diameter of acetabulum (Pearson’s correlation coefficient test)**

## DISCUSSION

Hip joint is one of the major joint of the body described as ball and socket variety of synovial joint.<sup>10</sup> It is necessary to evaluate the diameter of the acetabulum as a part of preoperative planning in order to estimate the size of the acetabular cup in surgical procedures of acetabulum especially in total hip arthroplasty. Morphometric parameters of the acetabulum such as diameter, depth and volume were measured and analyzed in this study.

The mean acetabular diameter was  $48.53 \pm 3.66$  mm revealed in this study, which was similar to the study conducted by Yugesh et al.<sup>11</sup> where the mean diameter was  $48.0 \pm 0.37$  mm. This study showed, the mean depth of acetabulum was  $27.88 \pm 3.33$  mm. It was consistent with Devi et al.<sup>12</sup> where mean depth was  $28.32 \pm 1.32$  mm. Mean volume of acetabulum was  $32.14 \pm 7.55$  ml in this study. Roshan et al.<sup>13</sup> observed almost similar result ( $30.83 \pm 4.6$  ml). This similarity occurs probably due to both study were done in south asian population.

The mean diameter was  $48.31 \pm 3.54$  mm on the right side and  $48.75 \pm 3.78$  mm on the left. It was similar to the findings of Yugesh et al.<sup>11</sup> where the mean diameter on right side was  $47.4 \pm 0.27$  mm and left side was  $48.0 \pm 0.37$  mm. The mean depth was  $27.79 \pm 3.29$  mm on the right side and  $27.97 \pm 3.39$  mm on the left side. It was near to the study done by Bollavaram et al.<sup>14</sup> where the mean depth was  $26.30 \pm 3.10$  mm on right side and  $27.10 \pm 3.57$  mm on the left side. Mean volume was  $31.63 \pm 7.01$  ml on the right side and  $32.68 \pm 8.08$  ml on the left revealed by the current study. Another indian study<sup>14</sup> showed mean volume of acetabulum was found  $28.04 \pm 6.16$  ml on the right and  $26.86 \pm 6.46$  ml on the left side which was closely similar to this study. This similarity was possibly due to same geographic population. The Independent sample t-test was used to compare difference of mean ( $\pm$ SD) of diameter, depth and volume of acetabulum of right and left side. The diameter, depth and volume were higher in left side than right. All the parameters were statistically non-significant ( $p > 0.05$ ). To observe the correlation between diameter and depth of acetabulum Pearson's correlation

coefficient test was done and statistically significant positive correlation was found between the depth and diameter of acetabulum. ( $r = 0.55$ ,  $p < 0.001$ ). This study was consistent with the observations of Gangavarapu et al.<sup>15</sup> ( $r = 0.2395$ ,  $p < 0.001$ ). Positive significant correlation was also found by Arunkumar et al.<sup>16</sup> ( $r = 0.388$ ,  $p < 0.001$ ) and Aksu et al.<sup>3</sup> ( $r = 0.498$ ,  $p < 0.001$ ). The correlation test was used to investigate the relationship between acetabular diameter and depth. It was necessary for diagnosis and surgical treatment of total hip arthroplasty.<sup>17</sup> A larger acetabular diameter might also have a deeper acetabulum.

Purposive sampling technique and small sample size were the limitation of this study. More elaborate studies involving samples from different area and different populations in Bangladesh should be required.

## CONCLUSION

Diameter, depth and volume of acetabulum of dry hip bones were slightly higher in left side than right in adult human. Morphometric studies of hip bones are of great importance not only for the anatomist and anthropologists, but also for the astrologists, forensic medicine experts and orthopedicians.

**Acknowledgments:** Authors are grateful to all the staffs and students of Rajshahi Medical College, North Bengal Medical College, Shaheed M Monsur Ali Medical College and Khwaja Yunus Ali Medical College for their supports.

**Conflict of Interest:** None

## REFERENCES

1. Standring S, Ellis H, Healy J, Johnson D, Williams A, Collins P, et al. The anatomical basis of clinical practice. Am J Neuroradiol. 2005; 26(10): 2703.
2. Goren H, Yemini. Global citizenship education redefined—A systematic review of empirical studies on global citizenship education. Int J Educ Res. 2017; 82: 170-183.
3. Aksu FT, Ceri NG, Armand, Tetik S. Morphology and morphometry of the acetabulum. J DEU Med. 2006.20(3): 143-148.

4. Solomon LB, Donald W, Henneberg HM. The variability of the volume of os coxae and linear pelvic morphometry. Considerations for total hip arthroplasty. *J Arthroplasty*. 2014; 29(4): 769-776.
5. Murray RO. The aetiology of primary osteoarthritis of the hip. *Br J Radiol*. 1965; 38(455): 810-824.
6. Denham RA, Alexander WL. Arthroplasty of the hip. *J Bone Joint Surg*. 1957; 39(4): 614-622.
7. Zeng Y, Wang Y, ZhunZ, Tang T, Daib K, Qiu S. Differences in acetabular morphology related to side and sex in a Chinese population's Anat. 2012; 220(3): 256-262.
8. Taher SA. Surface area of the acetabular cavity in contour and its capacity in man and in great apes. *Anat Soc India*. 1969; 18: 84-90.
9. Varodompun N, Thinley T, Visutipol B, Ketmalasiri B, Pattarabunjerd N. Correlation between the acetabular diameter and thickness in Thais. *OrthopSurg*. 2002; 10: 41-44.
10. Williams PL, Warwick R, Dayton. In: *Grays Anatomy*, 39th edition, London: Longmans, Churchill Livingstone publishers, 1989; 1440.
11. Yugesh K, Kumar S. Morphometric analysis of acetabulum and its clinical correlation in south Indian population. *Int J Appl Res*. 2016; 2(6): 1011-1014.
12. Devi T. B, & Philip X. Morphological and morphometrical study. *J Pharm Bio Chem Sc*. 2014; 5(6): 793-799.
13. Roshan S Gautham K. Morphometrics study of acetabulum in adult dry human pelvic bone. *Int J Orthop Sci*. 2015; 1(4): 27-28.
14. Bollavaram P, Gautham K, Jayalakshmi PV. Study of morphometric analysis of acetabulum and its clinical correlation in South Indian population. *Int J Anat Res*. 2022; 10(2): 8352-8358.
15. Gangavarapu S, Muralidhar RS. The study of morphology and morphology of acetabulum on dry bones. *Int J Anat Res*. 2017; 5(42): 4558-4562.
16. IndurjeethK, IshwarkumarS, Pileup. Morphometry and Morphology of the Acetabulum Within the Black African Population of South Africa. *Int J Morphol*. 2019; 37(3): 971-976.
17. Baharuddin MY, Zulkifly AH, Kadir MRA, Saat A, Aziz AA, Lee MH. Morphometric study of the acetabular in Malay population normal hips and its clinical applications. *Med Sci*. 2011; 11(5): 213-219.